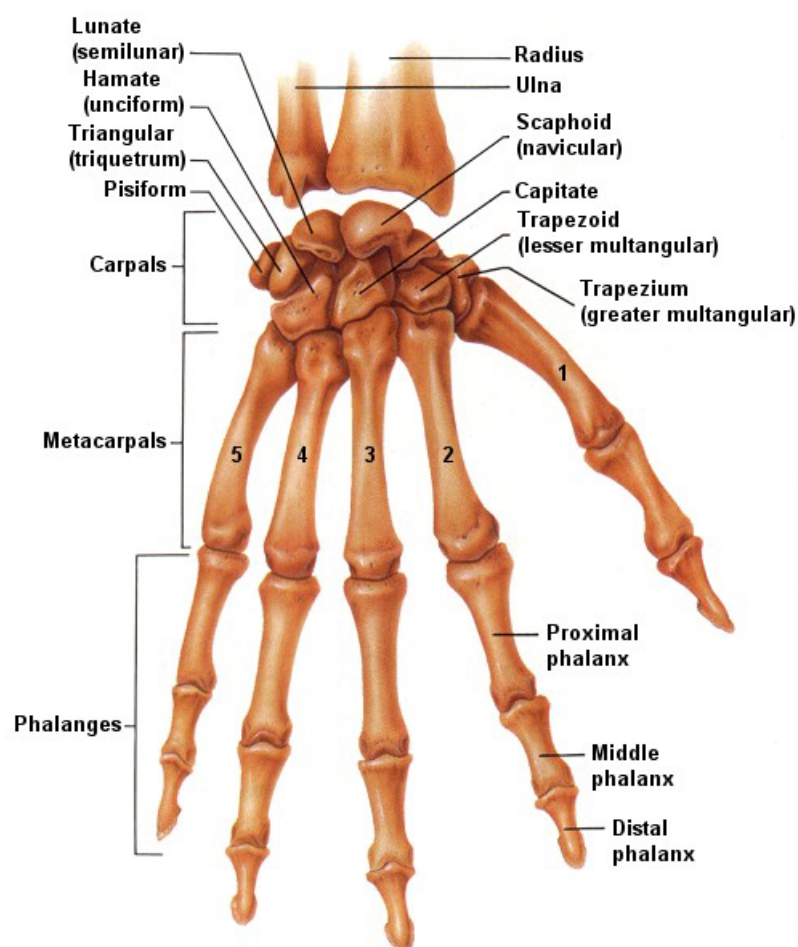


Below is a diagram showing the main bones together with written text on their order of compilation.



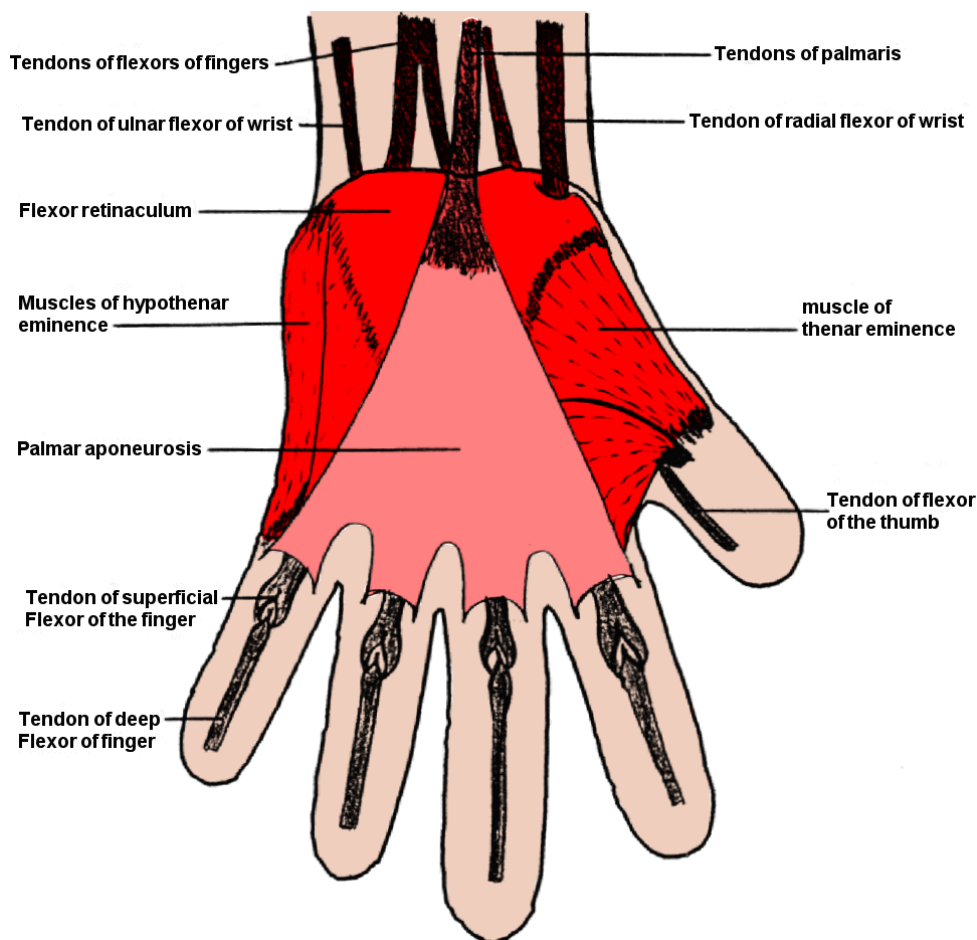
The hand and wrist contain twenty-seven bones and tendons, eight carpals, five metacarpals and fourteen phalanges.

The eight carpals make-up the wrist. These are small bones arranged in two rows of four. Each bone has a specific name as indicated on the previous diagram.

The palm of the hand contains the five metacarpal bones. The head of these bones, commonly termed the knuckles, can be seen when you make a fist, pulling the skin tightly over them.

The phalanges make-up the bone structures of our fingers and thumb. The fingers consist of three phalanges, whilst the thumb has only two.

MUSCLES OF THE HAND



HOW ARE OUR HANDS ABLE TO MOVE?

The contraction and extension of muscles manipulate the wrist, hands and fingers. Anterior muscles cause the hand and fingers to flex or bend, whilst the posterior muscles extend or lengthen the hand and fingers. The intrinsic muscles located in the palm of the hand provide further movement, which assist in further movement of the fingers.

The thumb plays a very important role in the efficient working of our hand. Only when the thumb is damaged and unable to be used do we realise just how much we need it, for picking objects up, holding objects or performing everyday tasks.

There are several problems that occur in the hands, which prevent complete movement and/or pain in the hands and arms. We are now going to look at a few of these in detail.

Repetitive Strain Injury

This is an increasingly common problem affecting a wide range of the population. It is only within the last few years that the medical profession has accepted that this injury is related to the type of work we do. For those working for long hours at a keyboard, this injury is becoming very common. Due to the change in the hand position from the original style of typewriter to the modern keyboard, our wrist position had changed dramatically. No longer are we taught to hold the wrists up and drop the fingers onto the keys, as our predecessors were. Many operators now place the heel of the wrist on the desk whilst they type. This causes the muscle tendons of each finger to become restricted at the wrist, thus causing inflammation. This in turn causes pain in the hands and arms. In severe cases, problems in the upper arm and shoulders will also occur. By placing a support under the wrist, freedom of movement of the tendons can be regained.

This problem also occurs when using modern technology such as shop scanners i.e. at the supermarket. Because of the nature of the job, the operator is constantly performing a repetitive movement, which in turn can cause inflammation. Any task that involves repeating an action over and over again can result in repetitive strain injury. The use of anti-inflammatory drugs can alleviate the problem in the short term, but for complete alleviation, only rest and perhaps a change of job is the answer.

This problem is something that most therapists should be aware of, especially Reflexologists and masseurs. The very nature of these jobs is repetitive. Always ensure that a rest time is taken between giving treatments. This allows any tension in the hands to be released and prevents any injury occurring. Many therapists, masseurs especially, do not recognise that the injury is present until the damage has been done. The result is a need to take time off and in some cases, the inability to continue in their profession.

Carpal Tunnel Syndrome

This is a painful ailment caused by the entrapment of either the median or ulnar nerve at the wrist. A membrane on the underside of the wrist, and the wrist bones forms the carpal tunnel. The bones are bound together by this membrane. Through this tunnel pass the median and ulnar nerves, which carry messages to and from the hand and the brain. When an entrapment of either of these nerves occurs, the messages become confused and mobility is painful and restricted.

There are two distinct results of the pinching of these nerves. When the median nerve is trapped, due to the swelling of the tissue within the carpal tunnel, tingling or numbness occurs in the thumb, index and middle fingers. When the ulnar nerve is trapped, the same symptoms occur in the little and ring fingers. This is called pisiform hamate syndrome as it relates to the two small bones of the same name found on the outer edge of the hand.

Raynaud's phenomenon

This is a fairly uncommon condition that affects the fingers and toes. Caused by a circulatory disorder, the small arteries become hypersensitive to cold. These contract causing the blood supply to be restricted to the fingers and toes, resulting in the symptoms of coldness to these areas and a bluish appearance due to the lack of oxygenated blood. This condition can cause pain and is cosmetically disfiguring.

Osteoarthritis

This is caused by a flaking of the smooth lining of the bones of the finger joints, although it can appear in any of the human joints. As this flaking continues, the breaking-down of the cartilage reveals the underlying bone, which thickens and distorts. This causes a restriction of movements and pain. The joints become stiff and swollen.

Tenosynovitis

This is commonly known as triggerfinger. The synovium is the membrane that forms a sheath to the tendons of the fingers and thumbs. It provides free movement to the tendons. This membrane becomes inflamed and swollen, causing it to tighten or narrow. This results in restricted movement of the tendons, which prevents the straightening of the fingers. The area over the tendon becomes tender to the touch, making the affected finger or thumb painful. A cracking noise can often be heard when the finger is moved. At the onset of this problem, rest can result in a complete recovery.

Clubbed Finger

This is the result of a chronic lung disease, although why is unknown. The tips of the fingers become flattened and spatula shaped, the cuticles disappear and the fingernail curves around the end of the finger. There is no known cure.

Ganglion

A ganglion appears as a small lump under the skin, at the wrist. This is due to an accumulation of the thick fluid in the joint capsule or tendon, which causes a swelling. Their size and texture may vary but they are usually the size of a pea and either hard or soft. Although they usually cause no pain, they are obstructive and unsightly. At this point they can be removed but will sometimes disappear of their own accord.

Dupuytren's Contracture

Dupuytren's Contracture is a common condition in men over the age of forty and is also hereditary. Only the little and ring fingers are affected by this disease, but further symptoms may be evident. Through the thickening and shrinkage of the tough, fibrous tissue under the skin on the palm of the hand, the fingers remain permanently bent at the knuckles. There may also be a thickening to the pads found at the base of the other fingers. In severe cases, surgery may be needed to release the fibrous tissue.

THE FINGER NAILS

Whilst injury is the most common cause of damage to the fingernails, our diet and general health also have an effect. Discoloration or deformity can be symptoms of disease in the body. It should be noted that prior to giving a hand reflexology treatment, the condition of the fingernails should be assessed as they can provide a good indication as to the wellbeing of the recipient.

Psoriasis

This is a stress-related ailment that affects the skin and the fingernails. The nails become thick, pitted and separated from the skin beneath.

Paronychia

Paronychia is an infection to the skin adjacent to the fingernail due to the presence of bacteria or yeast microbes. It affects the nail fold, causing it to become painful, red and swollen. Pus may also be expelled from the cuticle, which lifts away from the base of the nail due to pressure. In some cases, a thickening and discoloration of the nail may also occur.